



**PATIENT**

Max Martin

**SPECIES**

Canine

**BREED**

Greyhound

**SEX**

Male Neutered

**AGE**

7 years

**WEIGHT**

89.1lbs

**INTERPRETED BY**

Maggie Machen Lamy,  
DVM, DACVIM  
(Cardiology)

**IMAGING PERFORMED BY**

Kim Liedberg

**HOSPITAL NAME**

SVS Imaging WI

**REFERRING VET**

Dr. Juleen

**INVOICE**

25433

**DATE**

7/19/22

**PRESENTING CLINICAL SIGNS**

History: Grade 3/6 heart murmur. History of seizures since 2020, on Phenobarbital 97.2mg BID, last seizure was about 1 month ago and has one every 2-3 months. BCS 6/9.

**ELECTROCARDIOGRAPHIC FINDINGS** \*Note: Single lead ECGs are evaluated as a rhythm strip. Morphology/MEA cannot be definitively commented on.

A single lead ECG is available; 25mm/s, 10mm/mV. The average heart rate is 200bpm (range 150-50bpm). No identifiable P waves with an irregularly irregular rhythm, most consistent with atrial fibrillation.

ECG diagnosis: Rapid atrial fibrillation.

**ECHOCARDIOGRAM FINDINGS**

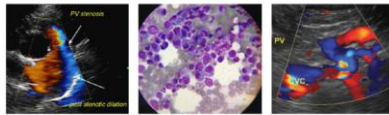
2D, m-mode, color flow and doppler imaging is available. Diffuse thickening of mitral valve leaflets with no significant prolapse into the left atrial lumen. Severe eccentric mitral regurgitation with marked left atrial dilation. Moderate LV dilation with adequate myocardial function. The tricuspid valve appears thickened with mild tricuspid regurgitation. Mildly elevated TR velocity. Mild right heart dilation. The pulmonic and aortic valves are normal in morphology and mobility. Normal pulmonic and aortic outflow velocities. No aortic and mild pulmonic insufficiency. Scant pericardial and no pleural effusion noted. No cardiac tumors observed. Irregular rapid rhythm throughout.

**CARDIAC CHART**

CANINE CARDIAC PARAMETERS	MR VMAX (m/s)	TR VMAX (m/s)	LA/AO (Boon method)	LA/AO (Heart Base; Swe)	FS (%)	EF (%)	EPSS (cm)
NORMAL PARAMETER	4.5-5.5	<2.7	1.3	<1.6	28-40	40-100	<0.6
PATIENT	5.2	2.9	2.0	2.8	43	62	1.2
CANINE CARDIAC PARAMETERS	HR (BPM)	AV VMAX (m/s)	PV MAX (m/s)	BODY WEIGHT (kg)	LA 2D short axis Base view (cm)	LVIDd Avg; 2D and m-mode short axis (cm)	LVIDs Avg; 2D and m-mode short axis (cm)
NORMAL PARAMETER	50-100	0.7-1.7	0.7-1.6	BELOW	BELOW	BELOW	BELOW
PATIENT	200	2.5	1.4	40.4	6.4	6.5	4.3
*Normal chamber parameters expressed as a mean value (SD)				3	1.27 (5.3)	2.46 (2.46)	1.36 (5.5)
<b>BODY WEIGHT DEPENDENT PARAMETERS</b>				5	1.40 (4.5)	2.74 (5.2)	1.60 (4.7)
<i>*Note: All measurements based upon multi-modal images and methods. An average value is reported.</i>				10	1.50 (3.8)	3.27 (3.5)	2.06 (3.1)
				15	1.83 (2.0)	3.71 (2.4)	2.43 (2.1)
				20	2.02 (1.9)	4.14 (2.2)	2.80 (2.0)
				25	2.18 (2.4)	4.48 (2.9)	3.10 (2.5)
				30	2.33 (3.3)	4.83 (3.9)	3.39 (3.4)
				35	2.48 (4.3)	5.17 (5.0)	3.69 (4.5)
				40	2.62 (5.2)	5.48 (6.1)	3.96 (5.4)
				50	2.88 (7.1)	6.07 (8.3)	4.46 (7.4)

**INTERPRETATION OF THE FINDINGS & FURTHER RECOMMENDATIONS**

Chronic degenerative valve disease causing severe mitral and moderate tricuspid regurgitation. Severe CVD has progressed to 4 chamber dilation and consequently rapid atrial fibrillation (AF)

**PATIENT**

Max Martin

and congestive heart failure. Pericardial effusion is due to right heart failure secondary to tachycardia/AF and there is high risk for left-sided failure as well. Mild pulmonary hypertension is noted which is likely secondary to active congestion. No additional issues are identified.

**SPECIES**

Canine

AF is characterized by disorganized contractions of the atria leading to an irregular heart rhythm. The irregular heart rhythm rarely causes clinical signs in dogs. However, atrial fibrillation also usually causes an increase in the heart rate, and this leads to clinical signs and CHF as we see here. Development of AF and CHF requires lifelong diuretics and management of the structural disease in addition to the arrhythmia.

**BREED**

Greyhound

Unfortunately, dogs with CHF and AF are at high risk for complications such as recurrent congestive heart failure, malignant arrhythmias, left atrial tear and sudden death. Medications and close monitoring will help give the best prognosis possible, however the average survival time with this condition is <6 months.

**SEX**

Male Neutered

Goals of therapy include correcting water retention, improving myocardial contractility, afterload reduction, and heart rate control. Full cardiac support including aggressive diuresis is indicated, due to the high risk for decompensation with rapid arrhythmias and severe disease. Medical management is recommended as below with a guarded to poor prognosis. The target heart rate is 140-160bpm in hospital.

**AGE**

7 years

**WEIGHT**

89.1lbs

Please monitor at home for cough, lethargy, inappetance, collapse/fainting episodes or increase in respiratory rate or effort. Monitoring of sleeping breathing rates is recommended to screen for recurrent CHF at home. Moderate activity restriction is advised. Omega fatty acid supplementation and mild salt restriction may be of some long-term benefit.

**INTERPRETED BY**

Maggie Machen Lamy,  
DVM, DACVIM  
(Cardiology)

**PLAN**

Institute Spironolactone 1-2mg/kg PO q12 hours. Institute Lasix/Furosemide 1-2mg/kg PO q8h for 3-5 days, if doing well at that time decrease to q12h going forward. Administer Pimobendan 0.3mg/kg PO q12 hours. Institute Diltiazem 1-2mg/kg PO q8 hours. Once eating well at home and BP is documented > 130mmHg, institute Benazepril 0.5mg/kg PO Q12h.

**IMAGING PERFORMED BY**

Kim Liedberg

Recheck heart rate in 5-7 days with target being 140-160bpm in hospital (stressed). If persistently >180bpm, institute Digoxin 0.005mg/kg PO q12h.

Screening renal panel and digoxin level in 5-7 days (6-8 hours post-am dose) to ensure tolerance of medications.

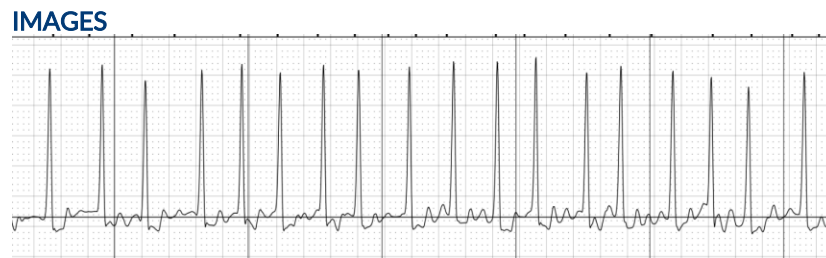
**HOSPITAL NAME**

SVS Imaging WI

Monitor renal values every 3-4 months lifelong. A recheck echocardiogram is recommended in 6 months to screen for progression.

**REFERRING VET**

Dr. Juleen

**INVOICE**

25433

**DATE**

7/19/22

**IMAGING PERFORMED BY**

svsmobileimaging.com 309-737-3070



**PATIENT**

Max Martin

**SPECIES**

Canine

**BREED**

Greyhound

**SEX**

Male Neutered

**AGE**

7 years

**WEIGHT**

89.1lbs

**INTERPRETED BY**

Maggie Machen Lamy,  
DVM, DACVIM  
(Cardiology)

**IMAGING PERFORMED BY**

Kim Liedberg

**HOSPITAL NAME**

SVS Imaging WI

**REFERRING VET**

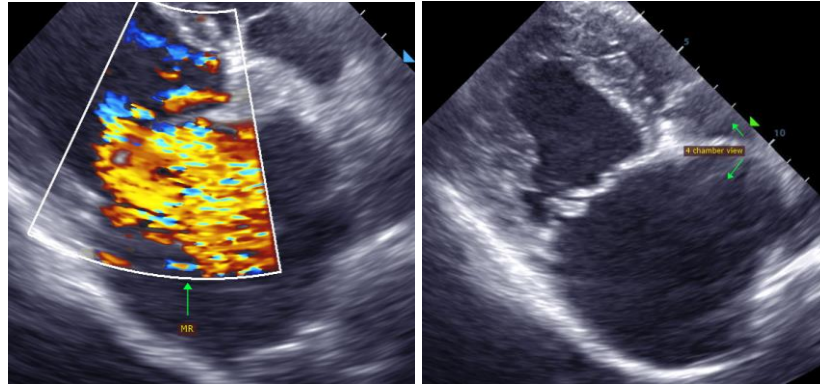
Dr. Juleen

**INVOICE**

25433

**DATE**

7/19/22



The information and recommendations provided are based on the images presented by the referring veterinarian. No evaluation can be communicated regarding pathology that was not visible in the image/video clips provided.

Thank you for this referral. If the clinical or image interpretation does not parallel your findings or if I can be of any further assistance, please contact me.

Maggie Machen Lamy, DVM  
Diplomate of the American College of Veterinary Internal Medicine (Cardiology)  
info@sonopath.com